

## Atypical Location of a Fibrokeratoma: A Case Report

**Julian Camilo Sánchez Guerrero\***, **Paulina Gabriela Pacheco**, **Diana Carolina Vasconez Celis**, **Josselyn Nicole Valarezo Sánchez**, **Bianca Fantin de Souza**, **Rossana Pereira da Conceição** and **Paulo Ricardo Martins Souza**

<sup>1</sup>Department of Dermatology, Santa Casa de Misericórdia de Porto Alegre Hospital, Brazil

\***Corresponding author:** Julian Camilo Sánchez, Department of Dermatology, Santa Casa de Misericórdia de Porto Alegre Hospital, Brazil; E-mail: [julian0032@hotmail.com](mailto:julian0032@hotmail.com)

**Received:** November 27, 2024; **Accepted:** December 17, 2024; **Published:** December 27, 2024

**Keywords:** *Fibrokeratoma; Atypical location*

### 1. Introduction

Acquired fibrokeratoma is a rare, benign fibroepithelial tumor that typically affects the hands and feet but has also been described on elbows, knees, and ankles. Involvement in other areas is uncommon. It usually presents as a solitary, pedunculated lesion and occurs more frequently in men than in women, with no apparent cause; however, trauma may be involved.

This case report describes an acquired fibrokeratoma located in the posterior cervical region, which is an atypical location [1,2].

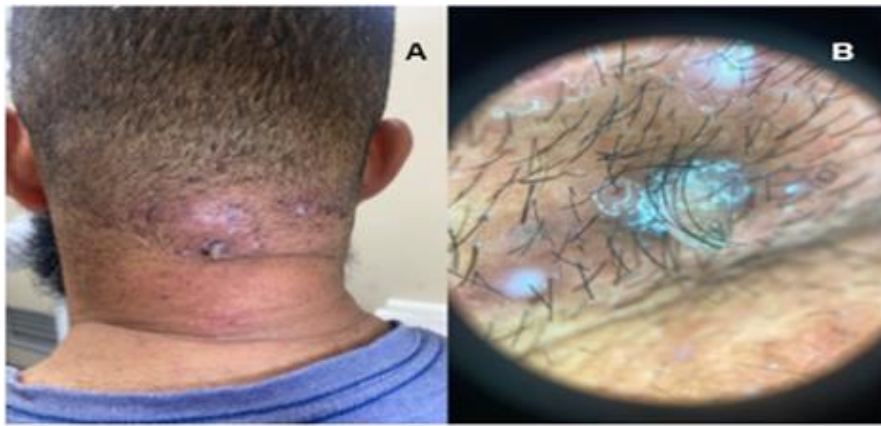
### 2. Case Report

37-year-old male patient reported lesions on the scalp for more than 10 years, with occasional pustule formation and a lesion in the central area of the posterior cervical region, which had an exophytic appearance (FIG. 1A).

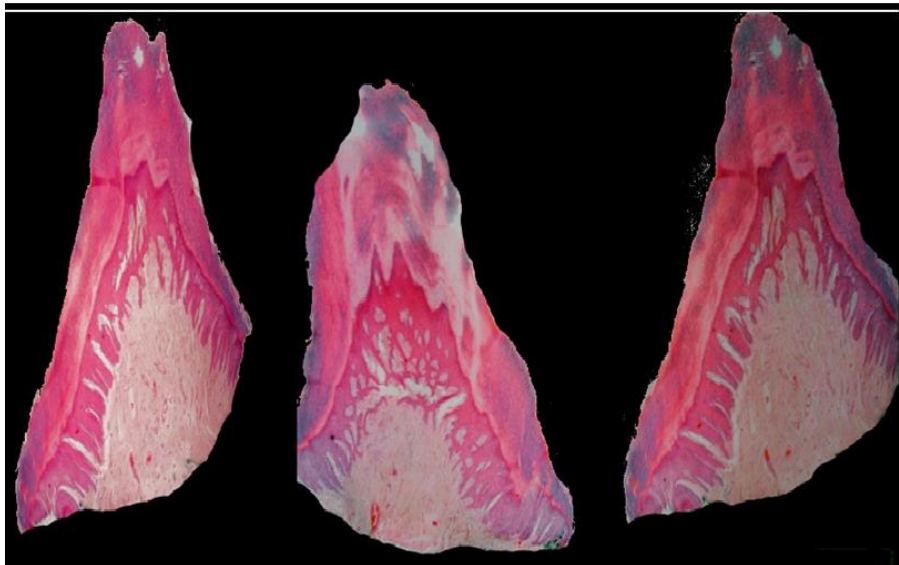Physical examination revealed a wedge-shaped lesion with a smooth surface on the nape of the neck, surrounded by an area with multiple fibrous papules and scar-like lesions (FIG. 1B). A biopsy was performed, revealing histopathological findings consistent with fibrokeratoma (FIG. 2).

**Citation:** Sánchez JC, Pacheco PG, Celis DCV, et al. Atypical Location of a Fibrokeratoma: A Case Report. *Arc Clin Exp Dermatol.* 2024;6(2):169.

©2024 Yumed Text.



**FIG. 1. Fibrokeratoma: A. Atypical location in the nape region. B. Dermoscopy reveals a wedge-shaped lesion with a smooth surface, surrounded by an area with multiple fibrous papules and scar-like lesions.**



**FIG. 2. The image shows acanthotic epidermis with hyperplasia and orthokeratosis. The center is composed of dense collagen mixed with fibroblastic proliferation and ectatic vessels.**

### **3. Discussion**

Fibrokeratomas are periungual tumors with a peculiar appearance, resembling a garlic bulb, and were once thought to be rudimentary supernumerary digits. Over time, multiple locations for these tumors have been documented, leading to changing the name to acral fibrokeratoma. Generally, they appear around 42 years of age and have a male predominance [3].

Typically, fibrokeratomas manifest as a single, protruding, keratinized lesion that primarily appears on the fingers. However, rare locations have been reported, such as the lower lip, elbow, nose, prepatellar area, nail bed, and heel. These lesions are usually less than 1 cm in size; when larger, they are classified as giant. Often, these tumors are underestimated due to their

similarity to various benign lesions, such as viral warts, granulomas, skin calluses, Koenen tumors, soft fibromas, and eccrine poromas, among others [1,2].

These lesions are generally asymptomatic, and their pathophysiology is not yet fully understood. Some authors describe trauma as a possible trigger, which may predispose fibroblasts to collagen neoplasm formation [2].

Histologically, fibrokeratomas have a high, hyperkeratotic dome shape, with a significant number of fibroblasts and few elastic fibers. Surgical treatment shows high cure rates, with lesion recurrence being unlikely [4].

We did not find any reports in the literature of fibrokeratoma occurring on the nape of the neck, making this likely the first documented case in this area.

#### REFERENCES

1. McCann MJ, Bonvillian J, Blazek CD. Acquired digital fibrokeratoma: a rare case study. *Foot (Edinb)*. 2020;44:101681.
2. Noriega LF, Chiacchio NG di, Chiacchio N di, et al. Unusual size, topography, and surgical resolution of an acquired fibrokeratoma. *An Bras Dermatol*. 2018;93(1):126-8.
3. McCann MJ, Bonvillian J, Blazek CD. (2020). Acquired digital fibrokeratoma: a rare case study. *Foot (Edinb)*. 2020;44:101681.
4. Noriega LF, Chiacchio NGD, Chiacchio ND, et al. Unusual size, topography, and surgical resolution of an acquired fibrokeratoma. *An Bras Dermatol*. 2018;93(1):126-8.